



**PATIENT PRESENTING CLINICAL SIGNS**

Sushi Savidge History: Grade 2/6 heart murmur. Increasing kidney enzymes; decreasing hematocrit, Prior history of gastric mucosal hypertrophy on PA Mobile ultrasound from 5/2019. Sedated with Torb.

**SPECIES ECHOCARDIOGRAM FINDINGS**

Feline 2D, m-mode, color flow and doppler imaging is available. The left ventricular wall is normal in dimension with regions of irregularity. Focal septal thickening. There is a mildly hyperechoic endocardium consistent with age-related fibrosis. Minimal remodeling. The papillary muscles are hyperechoic. The left atrium is normal in size. The right atrium is normal in size. The right ventricle appears normal. The mitral valve is normal in structure and mobility. No MR. The tricuspid valve appears normal in structure and mobility. No TR. Blood flow through both the LVOT and RVOT are normal in velocity. No effusions. No obvious cardiac tumors.

**BREED**

DSH

**SEX**

Female Spayed

**CARDIAC CHART**

**AGE**

9 years

**WEIGHT**

12.4lbs

**INTERPRETED BY**

Maggie Machen  
Lamy, DVM, DACVIM  
(Cardiology)

**IMAGING PERFORMED BY**

Rebekah Jakum, CVT  
ARDMS/RVT

FELINE CARDIAC PARAMETERS	BODY WEIGHT (kg)	HR (BPM)	IVSd (cm) (Moise, Pipers)	LVIDd (cm) (Moise, Pipers)	LVWd (cm) (Moise, Pipers)	FS (%)	EF (%)
NORMAL PARAMETER	-----	150-240	0.35-0.55	<2 (mean 1.5)	3.5-0.55	35-67	80-100
PATIENT	5.6	227	0.66	1.26	0.49	65	94
FELINE CARDIAC PARAMETERS	LA/AO (Boon)	LA/AO HEART BASE (Swe) (Abbott)	LA 2D short axis Base view (cm) (Abbott)		LVOT VEL (m/s)	RVOT VEL (m/s)	E max (m/s)
NORMAL	<1.5	<1.3	<1.2		<1.6	<1.3	<0.9
PATIENT	NM	1.3	1.1		1.2	0.9	NM

*\*Note: All measurements based upon multi-modal images and methods. An average value is reported.*  
Adapted from June Boon, Veterinary Echocardiography, 1998  
Abbott J & MacLean H JVIM 2006;20: 111-119, Moise et al. Am J Vet Res 47:1476, 1986. Pipers et al. Am J Vet Res 40:882, 1979.

**INTERPRETATION OF THE FINDINGS & FURTHER RECOMMENDATIONS**

Overtly normal cardiac structure and function with a focal septal thickening. This may be a normal variant or may suggest early hypertrophic disease. Follow up is advised. Mild fibrosis of the left ventricular wall is noted, which is likely a normal age-related variant. No significant valve leaks are noted, and flow through the great vessels is normal in velocity. No definitive cause is identified for the murmur in this study, making it likely physiologic in origin (i.e., secondary to tachycardia, volume changes, etc.). Given these findings and a normal LA dimension, no medications are indicated. A baseline BP and T4 are strongly recommended.

**HOSPITAL NAME**

Alburtis Animal Hospital

**REFERRING VET**

Dr. Smith

**INVOICE**

26994

**DATE**

10/19/22

No cardiac contraindication for general anesthesia. Should fluid or steroid therapy be indicated in the future, any cat should be monitored for intolerance (changes in RR/RE).

Monitor at home for signs of cardiac compromise, including respiratory changes and/or signs of a blood clot event (paralysis, neurologic changes).

Recommend recheck echocardiogram in 1 year to assess for any progressive issues or development of disease the pre-existing murmur may mask.



**PATIENT**

Sushi Savidge

**SPECIES**

Feline

**BREED**

DSH

**SEX**

Female Spayed

**AGE**

9 years

**WEIGHT**

12.4lbs

**INTERPRETED BY**

Maggie Machen  
Lamy, DVM, DACVIM  
(Cardiology)

**IMAGING  
PERFORMED BY**

Rebekah Jakum, CVT  
ARDMS/RVT

**HOSPITAL NAME**

Alburtis Animal  
Hospital

**REFERRING VET**

Dr. Smith

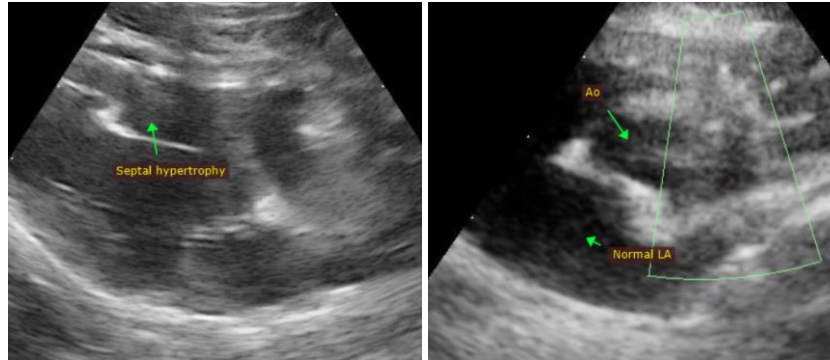
**INVOICE**

26994

**DATE**

10/19/22

**IMAGES**



The information and recommendations provided are based on the images presented by the referring veterinarian. No evaluation can be communicated regarding pathology that was not visible in the image/video clips provided.

Thank you for this referral. This report was generated using transcription software, and minor dictation errors may be present. If the clinical or image interpretation does not parallel your findings or if I can be of any further assistance, please contact me.

**Maggie Machen Lamy, DVM**  
Diplomate of the American College of Veterinary Internal Medicine (Cardiology)